

Case report

Mesentery of the descending colon, variation in the flexor carpi ulnaris insertion and renal cysts in a single cadaver

¹Dr. Anupam Baske , ²Dr. Asutosh Pramanik , ³Dr. Purnendu Rang , ⁴Dr. Parijat Mukherjee ,
⁵Dr. Bishwapriya Sinha, ⁶ Arunima Nag (Ray) , ⁷Dr. Maitreyi Mondal , ⁸Dr. Prof. (Dr.) Sudeshna Majumdar

^{1,2,3,4,5} Junior Resident, Department of Anatomy, North Bengal Medical College, Sushrutanagar, Darjeeling – 734012. West Bengal, India.

⁶Demonstrator, Department of Anatomy, North Bengal Medical College, Sushrutanagar, Darjeeling – 734012. West Bengal, India.

⁷Associate Professor, Department of Anatomy, North Bengal Medical College, Sushrutanagar, Darjeeling – 734012. West Bengal, India.

⁸Professor and Head of the Department of Anatomy, North Bengal Medical College, Sushrutanagar, Darjeeling – 734012.

Corresponding author: Dr. Sudeshna Majumdar

Abstract

In July, 2016, while doing the routine dissection in a 70 year old male cadaver, in the department of Anatomy, North Bengal Medical College, West Bengal, India, several variations were found in that cadaver. The descending colon was found to have a mesentery, multiple cysts were found in both the kidneys, the flexor carpi ulnaris tendon bifurcated to be inserted to the pisiform bone and to the flexor retinaculum in right forearm.

This case report will help us to enhance our knowledge in gross anatomy and will be of help for surgical, radiological or other clinical interventions in abdomen and superior extremity.

Key Words: Mesentery of the large gut, descending colon, renal cysts, flexor carpi ulnaris tendon.

INTRODUCTION

The alimentary tract develops as a single tube suspended in the coelomic cavities by dorsal and ventral mesenteries. The mesenteries of the intestines of the adult are the remnants of the dorsal mesentery. The migration and subsequent fixation of the parts of the GI tract produce the retroperitoneal segment of bowel (most of the duodenum, ascending colon, descending colon and rectum and four separate bowel loops are suspended by mesenteries of variable lengths. These are covered by the visceral peritoneum continuous with the parietal peritoneum covering the posterior abdominal wall. The fourth loop contains

the sigmoid colon and occasionally the distal descending colon [1].

The descending colon is 25-30cm in length and descends from the splenic flexure to the level of iliac crest, where it curves medially to become the sigmoid colon. In most adults it is retroperitoneal, but occasionally, it is more mobile, being suspended by the posterior abdominal wall by a short mesentery [2].

In adult each kidney is 15cm in length and 6 cm. in breadth. The left kidney may be 1.5 cm. longer than the right kidney. In the fetus and the newborn, the kidney normally has 12 lobules, in the adult, these

lobules are fused to present a smooth surface, although the traces of lobules may remain and mimic a renal mass [3].

It was thought that the renal cysts arose from clumps of vesicular cells, which persisted when the tips of the branches from the ureteric diverticulum fail to fuse with the metanephrogenic cap tissue derivatives. It is now believed that they are wide dilatations of a part of otherwise continuous nephrons. [4].

Flexor carpi ulnaris is the most medial muscle of the forearm. It arises by two heads from the humerus and ulna – connected by tendinous arch. The humeral head – from the medial epicondyle – via the common composite origin and the ulnar upper end – from the medial margin of olecranon and the proximal two-third of the posterior border of the ulna. The tendon of it is attached to the pisiform bone – sometimes attached to the flexor retinaculum and the fourth and fifth metacarpal bones. After attachment to the

pisiform bone, the tendon extends as pisohamate and pisometacarpal ligaments [5].

MATERIALS AND METHODS

While doing the routine dissection in a 70 year old male cadaver, in the department of anatomy, North Bengal Medical College, West Bengal, several variations were found in that cadaver in July, 2016. Dissection was done minutely, structures were observed in details and relevant photographs were taken.

OBSERVATIONS

In abdomen the descending colon was found to have a mesentery. Multiple cysts were found in both the kidneys, specially in the lower poles. The flexor carpi ulnaris tendon bifurcated to be inserted to the pisiform bone and to the flexor retinaculum in right forearm. The laterally deviated slip of the flexor carpi ulnaris may be the Palmaris longus tendon. On the left side, no such variation was found in forearm.

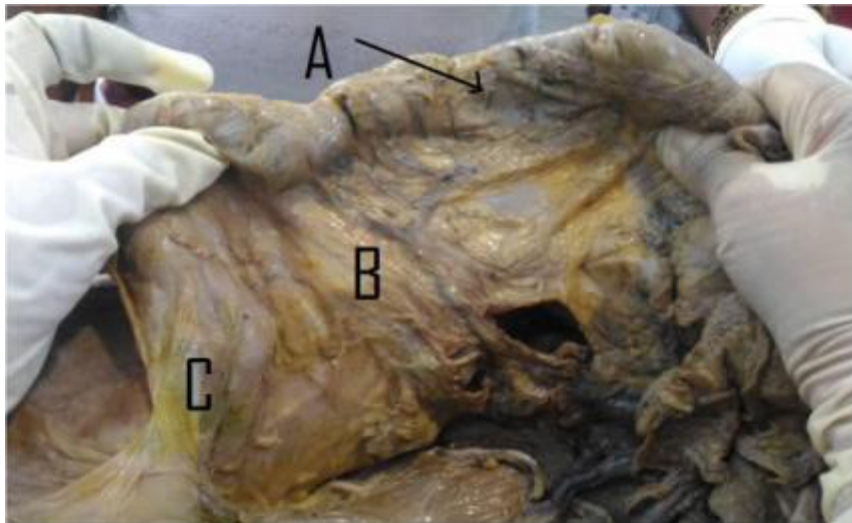


Figure – 1; The descending colon (A) and its mesentery (B), proximal to the sigmoid colon (C).

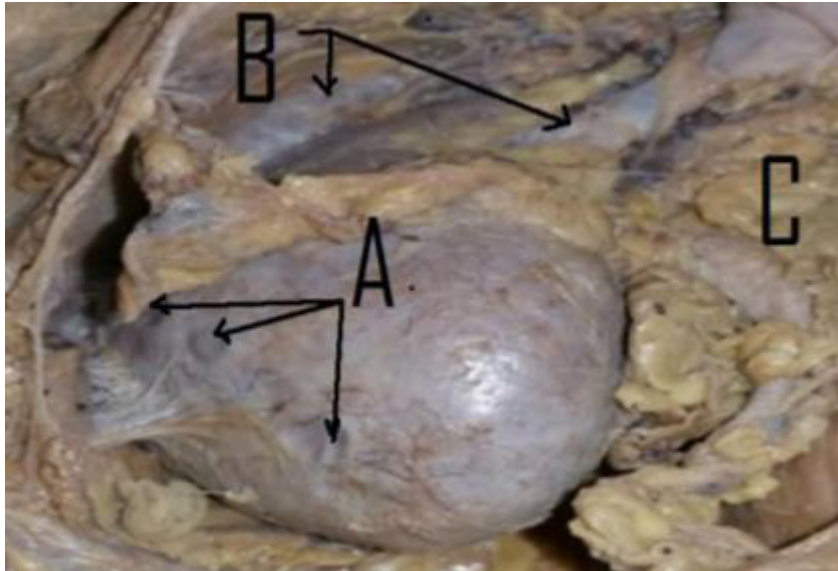


Figure – 2; The lower pole of the right kidney with three cysts (A), the renal vessels (B) and the ureter (C) are also visible.

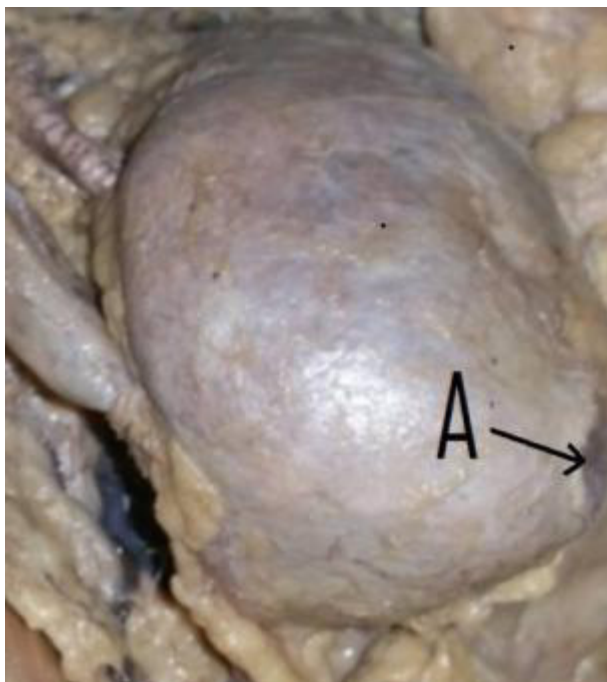


Figure – 3; the lower pole of the left kidney with a cyst (A).

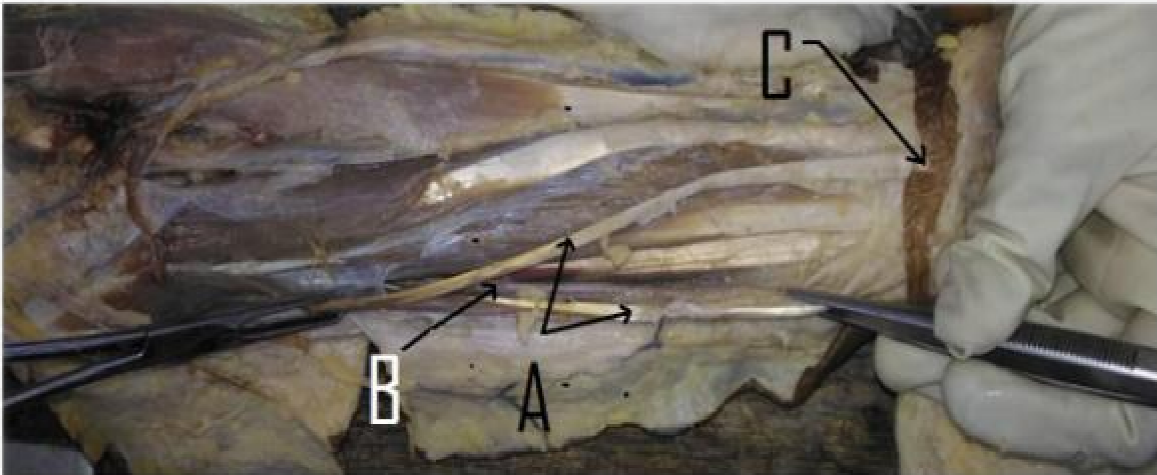


Figure – 4, The bifurcation of the tendon of flexor carpi ulnaris (A), beside the ulnar vessels (B) and nerve in the anterior aspect of the forearm. One slip of the tendon was inserted to the pisiform bone and the other slip was inserted to the flexor retinaculum (C).

DISCUSSION

In 2012 following detailed microscopic and electron microscopic examinations, the mesocolon was shown to be a single, continuous structure that commenced from the duodenojejunal flexure and extended to the level of the distal mesorectum. This simpler concept has enabled much advance to be made in different aspects of surgery on the colon and rectum with implications for sciences related to surgery, anatomy, and development [6, 7, 8].

Kidney cysts are round pouches of fluid that form on or in the kidneys. Kidney cysts can be associated with serious disorders that may impair kidney function. But more commonly, kidney cysts are a type called simple kidney cysts — noncancerous cysts that rarely cause complications.

It's not clear what causes simple kidney cysts. Typically, only one cyst occurs on the surface of a kidney, but multiple cysts can affect one or both kidneys. However, simple kidney cysts aren't the

same as the cysts that form with polycystic kidney disease.

Simple kidney cysts are often detected during an imaging test performed for another condition. Simple kidney cysts that don't cause signs or symptoms usually don't require treatment [9].

The tendon of **flexor carpi ulnaris** can be seen on the anterior aspect of the distal forearm. On a person's distal forearm, right before the wrist, there will be either two or three tendons. The tendon of the flexor carpi ulnaris is the most medial (closest to the little finger) of these. The most lateral one is the tendon of flexor carpi radialis muscle, and the middle one, not always present, is the tendon of palmaris longus.

The muscle, like all flexors of the forearm, can be strengthened by exercises that resist its flexion. A wrist roller can be used and wrist curls with dumbbells can also be performed.

These exercises are used to prevent injury to the ulnar collateral ligament of elbow joint. Ulnar entrapment

by the aponeurosis of the two heads of the flexor carpi ulnaris (FCU) muscle may cause cubital tunnel syndrome [10].

CONCLUSION

This case report will be of help to increase our knowledge in gross Anatomy and for surgical intervention in abdomen and forearm.

ACKNOWLEDGEMENT

We are grateful to all the members of the Department of Anatomy, North Bengal Medical College, Sushrutanagar, West Bengal, for their kind co-operation to complete this study.

REFERENCES

1. Standring S, Paul SH, Stringer MD, Sugarbaker PH. Peritoneum. Gray's anatomy – The Anatomical Basis of clinical practice. Elsevier, forty-first edition. 2016; p – 1098.
2. Standring S, Stringer MD, Lunnis PJ, Large Intestine. Peritoneum. Gray's anatomy – The Anatomical Basis of clinical practice. Elsevier, forty-first edition. 2016; p – 1145.
3. Standring S, Stringer MD, Guzzo TJ, Turigian GA. Kidney. Gray's anatomy – The Anatomical Basis of clinical practice. Elsevier, forty-first edition. 2016; p – 1237.
4. Standring S, Stringer MD, Guzzo TJ, Collins P, Jawaheer G, Sharpe RM. Urogenital development. Gray's anatomy – The Anatomical Basis of clinical practice. Elsevier, forty-first edition. 2016; p –1208.
5. Standring S, Birch K, Biant LC. Elbow and forearm. Gray's anatomy – The Anatomical Basis of clinical practice. Elsevier, forty-first edition. 2016; p – 850.
6. Wikipedia : the free encyclopedia, <https://en.wikipedia.org/wiki/Mesentery> , viewed on 27.12.2016.
7. Coffey JC (August 2013). "Surgical anatomy and anatomic surgery - Clinical and scientific mutualism". *The Surgeon*. **11** (4): 177–82.doi:10.1016/j.surge.2013.03.002. PMID 23597667.
8. Coffey JC, Sehgal R, Culligan K, et al. (June 2014). Terminology and nomenclature in colonic surgery: universal application of a rule-based approach derived from updates on mesenteric anatomy". *Techniques in Coloproctology*. **18**: 789–94.
9. Mayo Clinic , Patients care and Health info; kidney cysts, vide <http://www.mayoclinic.org/diseases-conditions/kidney-cysts/basics/definition/con-20035205>, viewed on 29.12.2016.
10. Wikipedia : the free encyclopedia, https://en.wikipedia.org/wiki/Flexor_carpi_ulnaris_muscle, viewed on 27.12.2016.